

Verminous Bronchitis in an Ox

A.B. Sarenasulastri^{1*}, A.C.M. Rahim¹, A. Suriakala¹, A.R. Salmeah²
and S.O. Zulkarnain¹

¹ Makmal Veterinar Kawasan Bukit Tengah,
14007 Bukit Mertajam, Pulau Pinang, Malaysia

² Department of Veterinary Service, Daerah Kerian, Perak, Malaysia

*E-mail: sarenavet@yahoo.com

ABSTRACT

Incidence of verminous bronchitis or pneumonia in Malaysia is an absolute rarity. Recently, lung samples obtained from a field post-mortem case unveiled evidence of this condition in an ox. Gross examination of the fresh unfixed chilled lungs received from Pejabat Veterinar Daerah Kerian, Perak revealed around 20-30 adult whitish worms of 3-5 cm in length and 0.1-0.2 mm in diameter in the bronchi of pneumonic areas. These worms were later identified as *Dictyocaulus viviparus*, a case which has been not diagnosed for the past few years. This finding indicated that the ox might have acquired the infection following exposure to heavy larval challenge. The use of anthelmintic may be helpful if it is given as an early prognosis for clinical condition of cough, and that dyspnoea and pyrexia are guarded. The management of grazing animals and pasture in Malaysia is very critical in preventing recurrence or occurrence of this condition.

Keywords: *Dictyocaulus viviparus*, verminous, bronchitis, ox

INTRODUCTION

Verminous bronchitis is also commonly known as bovine lungworm, parasitic bronchitis, verminous pneumonia, husk or hoose that causes differing degrees of respiratory signs within any affected group such as cough, tachypnoea, and dyspnoea. In severe cases, severe respiratory signs, with pyrexia which is usually fatal within 1 – 4 days later (Taylor *et al.*, 2007), are seen. It is caused by several nematodes, but *Dictyocaulus viviparus* is the main agent in cattle and deer. This lungworm belongs to the superfamily *Trichostrongyloidea* and has a direct life cycle (Aeillo and Mays, 1998).

MATERIALS AND METHODS

On 31st March 2009, MVKBT received fresh unfixed organ samples (lungs, liver, heart, spleen and kidney) of an ox from Pejabat Veterinar Daerah Kerian, Perak. The only complaints were inappetent and paleness prior to death. The case only involved 1 animal from a population of 35 heads. No other abnormal signs were noticed and the animal died 3 days later. The cattle were reared on extensive system where animals were allowed to graze.

Gross examination was conducted on a part of the lung sample received and the samples were sent for parasitology. Unfixed lungs, liver, and kidney were sent for bacteriology, while samples fixed in 10% buffered formalin were sent to the histopathology.

Received: 16 November 2009

Accepted: 11 January 2010

*Corresponding Author

RESULTS

The lung generally showed pneumonic lesions, along with the presence of 20-30 whitish worms (3-5 cm length and 0.1-0.2 mm diameter), within the bronchi. Both the kidney and liver were congested, while the heart and spleen showed no significant gross lesions. The worm was identified as adult *Dictyocaulus viviparus* (Figs. 1A and 1B).

Microscopically, bronchitis, alveolitis, and interstitial emphysema were seen in the lungs. Such cellular infiltration has led to narrowing and collapse of the bronchioles lumina and thickening of the alveolar septa. The larvae

could be seen within the bronchioles (Figs. 2A and 2B).

Bacteria of no clinical significance were isolated from the organs. Based on the pathology and parasitology findings, a case of verminous bronchitis due to *Dictyocaulus viviparus* was confirmed.

DISCUSSION

Verminous bronchitis can be caused by several parasitic nematodes, viz. *Dictyocaulus viviparus* in cattle and deer, *D. arnfieldi* in donkeys and horses, *D. filarial*, *Protostrongylus rufescens* and *Muellerius capillaries* in sheep and goats,



Fig. 1A: Adult *Dictyocaulus viviparus* with short trachea (as a difference)

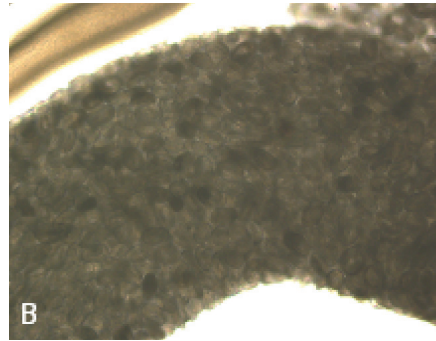


Fig. 1B: Gravid female with millions of ova containing fully developed larvae

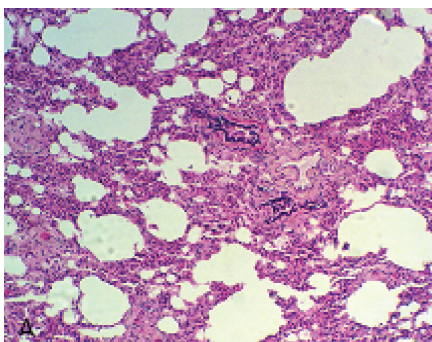


Fig. 2A: Cellular hyperinfiltration of the inflammatory cells causing bronchiolitis and collapsed of bronchioles, as well as alveolitis, thickening of the alveolar septa and interstitial emphysema

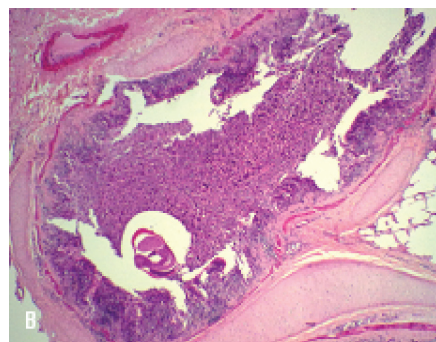


Fig. 2B: Cellular infiltrates of the inflammatory cells temporarily plug the lumina of the bronchus. Please note the cross-section of the lung worms inside the bronchus

Metastrongylus apri in pigs, *Filaroides osleri* in dogs and *Aelurostrongylus abstrusus* and *Capillaria aerophila* in cats (Taylor *et al.*, 2007). Diseases caused by the *Dictyocaulus spp.* are of most economic importance since it causes severe outbreaks of parasitic bronchitis in young grazing cattle (Taylor *et al.*, 2007).

The female worm is ovoviviparous and has a direct life cycle. The migration of the larvae (L1) from trachea, swallowed into the gastrointestinal tract and passed out into the faeces. It will later moult and become L3 in environment, get ingested again and penetrate the intestinal mucosa, moult in mesenteric lymph nodes and L4 travel up to lungs via lymph and blood circulation and break out the capillaries into the alveoli about 1 week after the infection. The final moult occurs in bronchioles and young adults, before moving up to the bronchi and mature. The pre-patent period is around 3-4 weeks (Aiello and Mays, 1998).

The pathogenesis of Dictyocaulosis can be divided into three phases (Taylor *et al.*, 2007), namely the pre-patent phase (around day 8-25), patent phase (around day 26-60) and the post-patent phase (around day 61-90). Pathogenic effects are dependent on their locations within the respiratory tract. The degrees of clinical signs can be classified as mildly affected (intermittent cough particularly during exercise), moderately affected (frequent cough at rest, tachypnoea and hyperpnoea with frequent squeaks, and crackles upon auscultation of lungs) and severely affected (severe tachypnoea and dyspnoea, open mouth breathing with head and neck outstretched, deep harsh cough, salivation, anorexic and sometimes mild pyrexia) which maybe fatal.

Microscopically, during the pre-patent phase, larvae in alveoli will lead to alveolitis, bronchiolitis, and bronchitis. Meanwhile during the patent phase, bronchial epithelium becomes hyperplastic and heavily infiltrated by inflammatory cells, particularly eosinophils. Macrophages and multinucleated giant cells can be seen around the eggs and larvae. There may be varying degrees of interstitial emphysema and oedema. In the post-patent phase, bronchial and peribronchial fibrosis may persist for weeks to

months. However, proliferation of the Type 2 pneumocytes, as a result of epithelisation causing interstitial emphysema and pulmonary oedema, can happen and this is frequently fatal and known as the post-patent parasitic bronchitis.

Diagnosis can be made based on the clinical signs, history of grazing as well as the post-mortem findings of the diagnostic presence of adult worms within the bronchi. Faecal sample yielded positive results during the patent phase. Meanwhile, serology (to detect antibodies against *D. viviparous*) can be used in the re-infection case, where seroconversion takes around 4-6 weeks and titre persists for 4-7 months.

An anthelmintic treatment (benzimidazoles, levamisoles or the avermectin/milbemycin) is helpful during early infestation period. However, one should be aware that it may exacerbate the clinical signs with a possible fatal termination in severe diseases. Prognosis is almost guarded for any calves which are dyspnoeic, anorexic, and possibly pyrexia.

The control and prevention of verminous bronchitis is best by immunizing all young calves with lungworm vaccine. However, it is only currently practiced and available in some parts of Europe. In Malaysia, the prevalence of the lungworms in cattle is not critical as compared to the cattle industry in Europe. Thus, the availability and efficacy of the vaccination programs are not yet critical and practical. Furthermore, it does not completely prevent the establishment of small number of lungworms. Therefore, controlling of pasture is very important as the transmissions of the larvae are indicated.

CONCLUSIONS

This is a case of pre-patent phase of *D. viviparous* infection as confirmed by the histopathological findings of cellular infiltration causing alveolitis, bronchiolitis and bronchitis with no obvious coughing noticed in this herd by either farmer of the VA. The mortality and morbidity were also found to be very low as the study only involved an ox. However, this might be the

beginning of an outbreak if proper measure was not taken. In addition, considerations should be emphasised on the clinical signs (cough) as well as poor/false/failure of the exact records of mortality and morbidity. This is especially so since *Dictyocaulosis* may be vague in terms of transmission and epidemiology.

ACKNOWLEDGEMENTS

The authors would like to thank to the Director, MVKBT staff (pathology, parasitology, and bacteriology section), and the staff of Pejabat Veterinar Daerah Kerian, Perak, for their help.

REFERENCES

- Taylor, M.L., Coop, R.L. and Wall, R.L. (2007). *Veterinary Parasitology*, 3(2), 80-84.
- Susan E. Aiello, Asa Mays and The Merck Veterinary Manual. (1998). *Lungworm Infection*, 1061-1064.